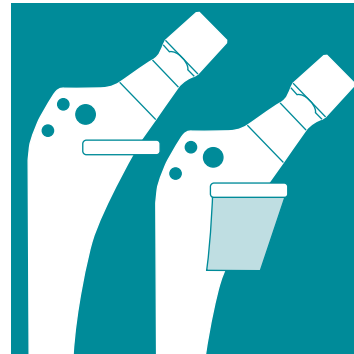

**VERSYS[®] CRC
(CEMENTED
REVISION/CALCAR)
HIP PROSTHESIS**



**Surgical
Technique
for Revision Hip
Arthroplasty
(with or without
Calcar Blocks)**

SURGICAL TECHNIQUE FOR VERSYS CRC (CEMENTED REVISION/CALCAR) HIP PROSTHESIS

BY:

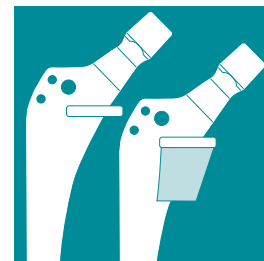
Dennis W. Burke, M.D.
Boston, MA

Harry E. Rubash, M.D.
Boston, MA

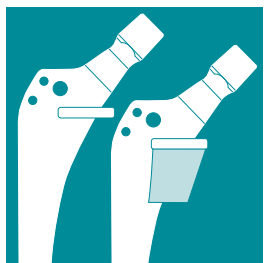
Steven F. Schutzer, M.D.
Hartford, CT

CONTENTS

DESIGN PHILOSOPHY	2
PREOPERATIVE PLANNING	2
SURGICAL TECHNIQUE	4
Incision and Exposure	4
Determination of Leg Length	5
Stem Removal	5
Loose, Standard Length Cemented Femoral Components	5
Loose, Cemented Long Stem Femoral Components	6
Loose, Cementless (porous and textured surfaces), Standard and Long Stem Femoral Components	6
Preparation of the Femoral Canal	7
Medial Bone Resection	8
Rasping	9
Trial Reduction (optional)	11
Distal Reaming (optional)	11
Inserting Provisional Stems	12
Trial Reduction	14
Canal Preparation	14
Assembling the Implant	14
Cement Introduction and Stem Insertion	15



Various components of the VerSys Hip System are covered by one or more of the following U.S. Patents: 4,281,420; 4,336,618; 4,491,987; 4,795,472; 4,963,155; 5,013,324; 5,018,285; 5,089,003; 5,156,624; 5,192,323; 5,326,362; 5,480,453; 5,496,375; 5,569,255; 5,624,445; 5,702,485; 5,725,596; 5,755,811; D397,220.



DESIGN PHILOSOPHY

Long stem femoral components are often indicated for the revision of failed femoral components associated with osteolytic defects around the distal end of a loose stem or cement plug. If there has been loss of more than 50% of the cortical bone thickness, a stress riser is created that may predispose the femoral shaft to fracture if the structural weakness is not bypassed by a distance of approximately two canal diameters below the defect. For similar reasons, long stems may be necessary to bypass femoral canal perforations or screw holes that may have been made at the time of the primary procedure or while removing cement at revision.

For bone loss in the proximal medial metaphyseal and diaphyseal regions, a calcar stem may be required to allow the surgeon to build-up the deficient calcar bone.

The *VerSys* CRC Hip Prosthesis accommodates the need for a long stem cemented revision implant for stage 1 and stage 2 femoral deficiencies, as well as for a modular cemented calcar implant for stage 3 deficiencies. It is designed to work with the *VerSys* System Rasp to achieve optimal placement and fixation. The rasp system allows preparation of a bony bed into which the prosthesis can be inserted with a circumferential cement mantle. The aggressive taper of the distal tip helps reduce the strains in the cement mantle around the distal tip. The addition of an external distal centralizer helps centralize

the implant distally. The prosthesis also incorporates an increased neck length and offset to help restore proper joint kinematics in revision cases.

If the proximal medial bone is unexpectedly weak or absent, it may be necessary to add height to the prosthesis intraoperatively. As a calcar stem, the *VerSys* CRC Prosthesis provides an opportunity to add build-up blocks of 10, 20, or 30mm to compensate for bone deficiencies. These blocks are designed to replace medial bone and minimize the need to remove lateral bone to insert the implant. The stem also has a transverse collar to provide excellent stress distribution in the region of the medial femoral cortex.

The surgical procedure is very flexible, offering a number of different surgical options, including:

- 1) Rasping with or without the use of a provisional
- 2) Rasping and reaming with or without the use of a provisional
- 3) Using a provisional only

PREOPERATIVE PLANNING

The key to successful revision THA is comprehensive planning to prepare for a variety of potential circumstances. This begins with careful preoperative templating.

Begin by obtaining a complete set of good quality radiographs, including:

- 1) An anteroposterior pelvis centered on the lesser trochanter

2) An anteroposterior and lateral of the femur

3) A shoot-through lateral of the hip

For patients with acetabular bone deficiency, Judet views, obturator, and iliac oblique are also helpful.

Mark the important reference points on the radiographs, including:

- 1) The existing center of rotation of the failed hip arthroplasty
- 2) The location of the anatomic center of rotation (based on either the contralateral hip, preoperative views of the failed hip, or by using the teardrop and Kohler's lines for reference.)
- 3) The offset of the failed hip arthroplasty
- 4) The preoperative offset
- 5) The level of the calcar

In addition, assess any acetabular and femoral bone deficiencies, angular or rotational deformities of the femur, as well as a variety of factors related to the failed implant.

The purpose of preoperative templating is to:

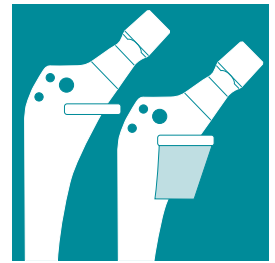- 1) Gain an accurate three-dimensional understanding of the bony anatomy
- 2) Estimate the stem size and length
- 3) Determine the possible centers of rotation of the reconstruction (anatomic or new hip center)
- 4) Predict limb lengths based on the hip center and height of the calcar in

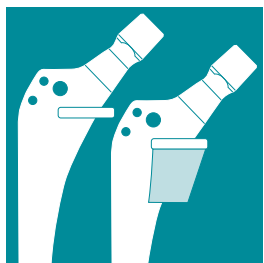
conjunction with clinical measurements and/or preoperative scanograms

- 5) Determine potential difficulties in implant removal and insertion
- 6) If necessary, plan the level and type of femoral or trochanteric osteotomy and the bed for its reattachment

When templating, it is important to appreciate that magnification of the size of the femur will vary depending on the distance from the x-ray source to the film and the distance from the patient to the film. The VerSys Hip System templates use standard 20 percent magnification, which is close to the average magnification on most clinical radiographs. Larger or more obese patients may have magnification greater than 20 percent because their osseous structures are farther away from the surface of the film. To determine the magnification of any radiograph, use a standardized marker at the level of the femur when making the film.

Template for the acetabular component first. In the absence of any significant bone deficiencies, select the hemispherical acetabular transparency that makes the best circumferential contact with the remaining bone stock, positioning the implant in 45 degrees of abduction. If there is major bone loss or socket break-out, template for a smaller acetabular component at a higher than normal hip center. For other types of complex bone deficiencies, plan the reconstruction against the best available bone stock, which may also be at a high hip center, or at the anatomic center with the





use of a large hemispherical component. Indicate these possibilities as potential centers of rotation on the radiographs.

Next, template for the femoral component to determine the optimum size and length of the femoral component, and its position. Clearly delineate areas of major osteolysis, stress risers, and points of angulation or malrotation, all of which influence the size and length of the stem required. Select the template that best fits the femoral canal on the AP, frog, and true lateral radiographs. The outline of the prosthesis is indicated by a solid line and the outline of the cement mantle created by the rasp is indicated by a dashed line on the template. Choose the largest femoral component that will fit into the diaphysis with an appropriate circumferential cement mantle. Align the femoral template so that it is centered in the diaphysis and then move the template so that the collar rests on the medial neck or medial femoral cortex. While aligning the femoral template in the canal, the presence of incongruities or an excessive bow or angulation in the AP or lateral planes will become evident. If the template does not fit, the actual stem will not pass down the canal during surgery. In this case, select another option such as a narrower stem, an osteotomy with straightening of the femur, or using a short stem with allograft struts to bypass stress risers.

After indicating the planned center of rotation on the radiograph, and the proper position of the femoral component,

determine the optimal neck length and offset. Note that this implant system has increased offsets and neck lengths compared to primary *VerSys* Stems. If the collar of the femoral template is within or below the lesser trochanter, position the template to the appropriate reference line for a calcar buildup block. These blocks are available in sizes to add 10, 20, or 30mm of height. Remember, adding buildup blocks reduces the stem length proportionally, and this should be taken into account when choosing the appropriate stem length to bypass stress risers.

SURGICAL TECHNIQUE

Incision and Exposure

The incision for revision surgery requires careful planning to minimize the possibility of wound healing complications. Begin by outlining the anatomic landmarks on the skin, including the greater trochanter, femur, iliac crest, anterosuperior iliac spine, and the interval between the tensor fascia lata and the gluteus maximus. Then mark the existing scars. Avoid crossing previous scars at an angle less than 60 degrees, and avoid distal-based skin flaps, both of which can lead to necrotic skin changes. Whenever possible, use a previous incision that can be extended proximally or distally. It is helpful to begin the incision distally in fresh tissue where the fascia lata does not adhere to the vastus lateralis.

The most common exposures for revision THA are: (1) the posterolateral approach

without a trochanteric osteotomy, (2) the true lateral approach with a standard trochanteric osteotomy, (3) the extended direct lateral or, (4) the extended trochanteric osteotomy (ETO). For complex acetabular reconstructions, trochanteric osteotomy provides the best exposure of the supra-acetabular ilium. The extended trochanteric osteotomy is particularly useful for extraction of well-fixed stems or for removal of difficult cement columns.

Alternatively, the posterolateral approach can provide excellent extensile exposure and mobilization of the upper femur for cement removal and bone grafting, especially when the femoral component is removed. This frequently entails release and transfer of the iliopsoas tendon, release of the short external rotators, complete capsulectomy, and release of the gluteus maximus tendon.

Determination of Leg Length

Once the exposure has been achieved, obtain a baseline leg length measurement before dislocation of the hip. There are several methods to measure leg length. One method is to attach the 3-prong leg length caliper to the wing of the ilium, just below the anterior-superior iliac spine. Alternatively, a tag suture can be placed proximal to the incision. Take a reference measurement to a point around the vastus ridge. Be sure to place the limb flat on the operating table in a fixed position of extension and rotation. Mark the outline of the limb on the drapes and use the outline for

reference so that the same position can be reproduced during trial reduction.

Intraoperative leg length measurements should be compared with predicted lengths based on the preoperative plan.

Stem Removal

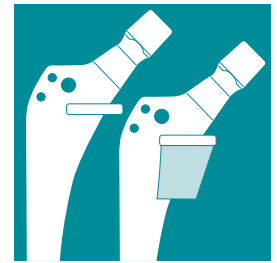Remove the implant from the femoral canal. The ease with which a femoral component can be removed will vary, depending on whether the stem is loose or well-fixed, cemented or cementless, regular or long stem. Each situation has inherent problems that should be anticipated.

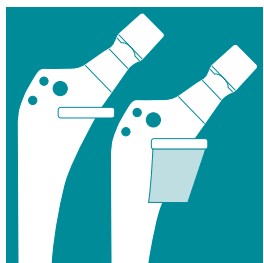
Loose, Standard Length Cemented Femoral Components

Excise all scar and membrane around the femur to completely expose the implant and cement mantle. If the stem has a collar and has subsided, new bone may have grown over the collar. Remove this bone and the wedge-shaped proximal/lateral cement mass before attempting to extract the stem. If the cement is not removed, it will serve as a reverse wedge and, as the stem is backed out, it may fracture the lateral cortex of the femur on the greater trochanter.

The stem removal method will depend on the following factors:

- 1) whether the failure occurred at the cement-metal interface or the cement-bone interface
- 2) whether the femoral head is modular or monoblock
- 3) whether there is an extraction hole, and
- 4) whether the stem has a collar or flange.





If the failure has occurred at the cement-metal interface, stem removal is usually much easier and can often be done manually or with an extraction hook and slap hammer. However, if the stem has failed at the cement-bone interface, removal may be difficult because of tenacious membrane that forms between the cement and bone. This becomes a problem primarily when the cement-metal interface does not disrupt as the femoral component is being extracted, and removal of the stem brings with it all of the adherent cement. If there are areas of osteolysis or angular deformity which led to an area in which the distal cement attached to the stem is wider than the medullary canal at any point, there is a possibility of fracturing the femur as the implant with cement is extracted. In this case, it is safer to disrupt the cement-metal interface, remove the stem first, and then remove the cement in small sections. If the stem has an extraction hole, use a hook and slap hammer to remove the stem. Exercise patience and great care to avoid damaging the femur during the extraction. A carbide tip punch has also been successful as well as the use of the Antonson U-shaped extractor for collared or monoblock stems.

Loose, Cemented Long Stem Femoral Components

Careful analysis of the AP and lateral radiographs is important to predict potential difficulty in removing these stems. If segments of the cement mantle, which are well-fixed to the stem, are also adherent to

osteolytic bone, there is serious risk of fracturing the femur with stem extraction. It is safer to make a window in the femur and remove the cement prior to extracting the stem. Beware of long stem cemented femoral components with a mid stem taper. Removal of this component is particularly difficult. In this case, the extended trochanteric osteotomy can be a major advantage.

Loose, Cementless (porous and textured surfaces), Standard and Long Stem Femoral Components

Removal of these implants can either be straightforward or deceptively challenging. In some cases, the femoral components may be “loose” but yet difficult to remove because of substantial fibrous tissue ingrowth. To disrupt this interface, use long flexible osteotomes, working circumferentially around the proximal portion of the implant. It may be necessary to osteotomize the trochanter for access to the lateral aspect of the stem. It may even be necessary to remove the prosthetic collar with a metal-cutting tool to allow access to the proximal interface. Alternatively, if this problem is anticipated, an extended trochanteric osteotomy down to the level of the distal end of the porous coating can provide excellent access to this interface. This is particularly useful for fully porous-coated or textured stems. Expose the lateral femur by elevating the vastus lateralis and marking the osteotomy to remove the lateral third of the femur to the length of the failed stem

if it is fully coated. Make a series of 1mm diameter drill holes, 5mm apart, along the planned osteotomy. Then complete the osteotomy with a sharp osteotome or microsagittal saw. Lift the bone off with extreme care from the underlying porous surface. Disruption of the medial interface can then be accomplished with a Gigli saw.

Preparation of the Femoral Canal

After removing the implant, inspect the metaphyseal and diaphyseal regions for a neocortex, sclerotic bone formation, and remaining bone cement in the case of a cemented implant. Use this information to choose the appropriate procedure for femoral preparation.

This VerSys CRC System contains femoral rasps and implant provisionals to guide the preparation of the femoral canal. A traditional rasping technique can be used to remove bone in the same manner as a primary surgery. In some cases with extensive endosteal osteolysis or enlargement, it may not be practical to use rasps. Instead, stem provisionals are used to choose the appropriate size and length of implant. The surgeon can decide intraoperatively which technique is most appropriate for the specific patient.

This technique will demonstrate the procedures used for cases with no calcar loss (Fig. 1), and cases with 20mm of medial cortical loss (Fig. 2).

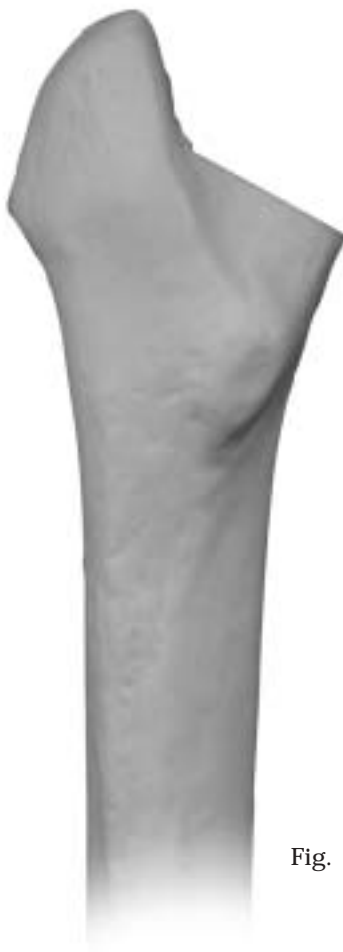

Fig. 1

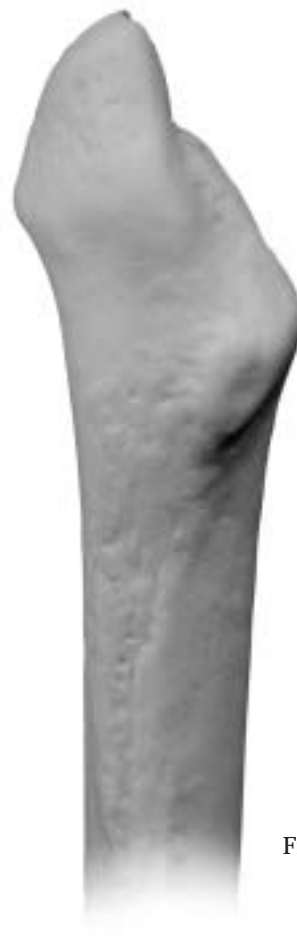
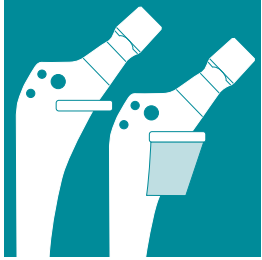
Fig. 2



Medial Bone Resection

Superimpose the Calcar Resection Guide on the proximal femur (Figs. 3 & 3a). The guides are available in 4 sizes to match the implant sizes. They are marked “CRC” for easy identification. Align the centerline of the Resection Guide with the centerline of the femur. Move the template proximally or distally to the correct height as determined by preoperative planning and intraoperative assessment. Then mark the level of the cut

with a saw or methylene blue line. The Calcar Resection Guides indicate the depth of cut necessary for the stem alone or with each calcar block. Choose the resection height which preserves femoral bone stock.

Cut the medial neck or calcar transversely for about 1cm to accept the implant collar (Figs. 4 & 4a). Then make the longitudinal

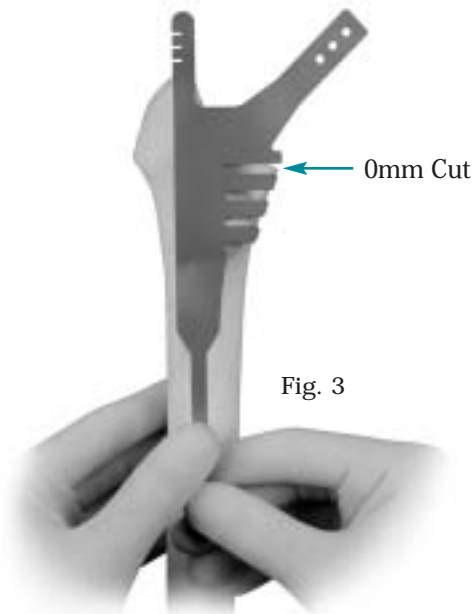


Fig. 3

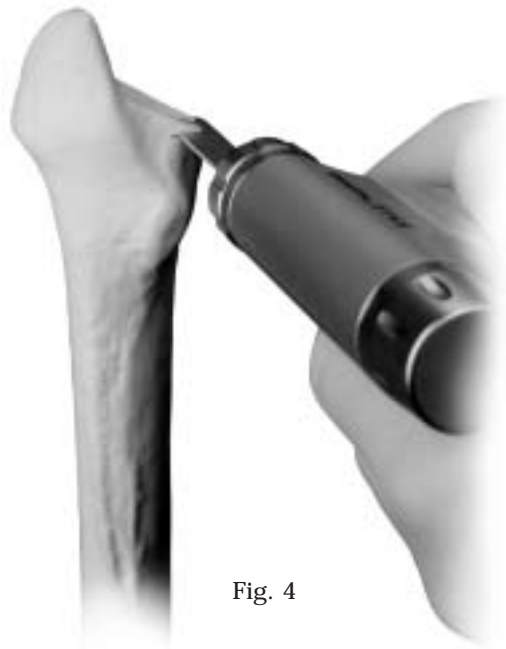

Fig. 4




Fig. 3a

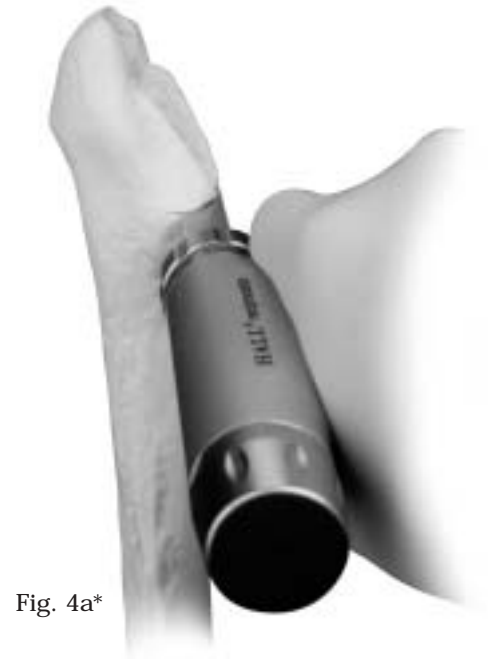

Fig. 4a*



cut in line with the long axis of the femur and in a plane matching the proper proximal femoral anteversion (Figs. 5 & 5a).

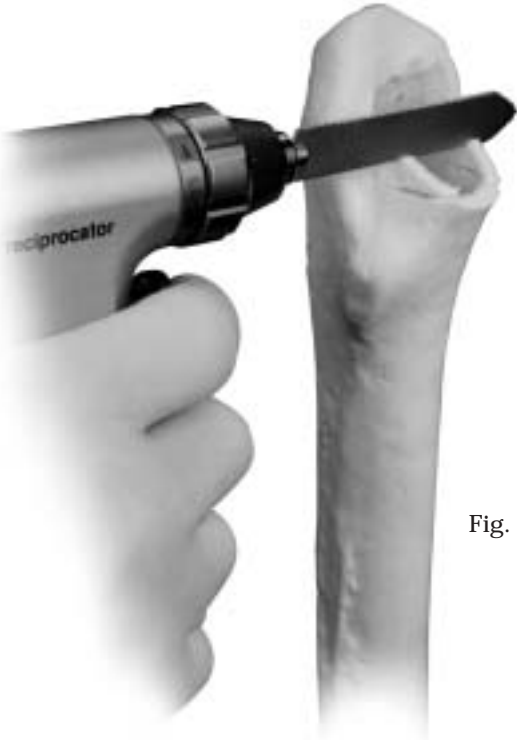

Fig. 5

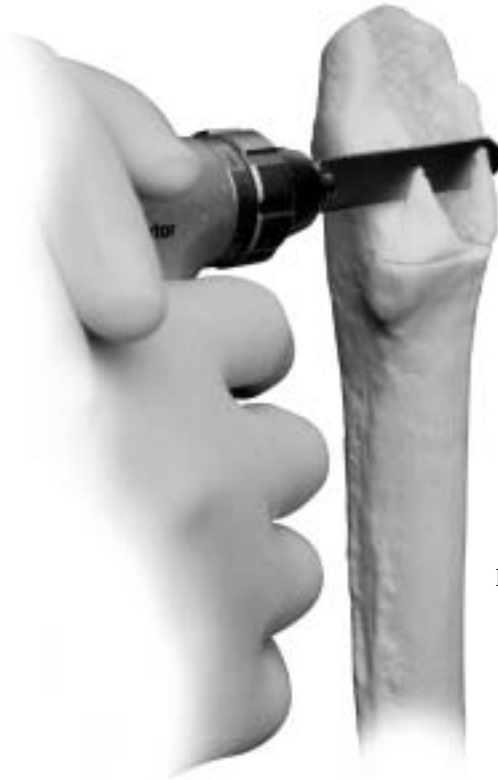

Fig. 5a


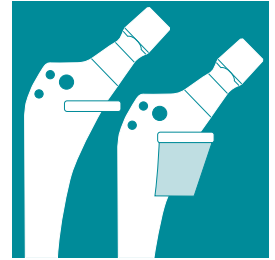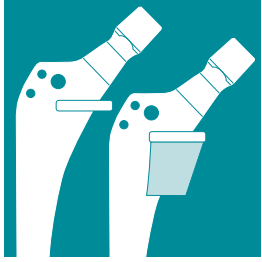


Fig. 6

Rasping

Use the *VerSys* system rasps when preparing the canal for the *VerSys* CRC implant. When performing a cemented revision or calcar procedure, do not use the Large Metaphyseal or Enhanced Taper rasps. These rasps are engraved with 'LM' or 'ET' near the trunnion for easy identification. Also, do not use the rasp alignment tips in a cemented technique. The threads on the tip of the standard rasp must be visible before rasping the canal (Fig. 6).



Depending on the approach, antevert the rasp between 0 and 20 degrees when driving it into the medullary canal. The amount of femoral rasp anteversion is related to the natural anteversion of the patient's femoral neck and the version of the acetabular component. Start with a rasp 1-2 sizes smaller than the size selected during templating (Fig. 7). The rasp should advance with each moderate tap of the mallet. Insert the rasp to the level of the most proximal tooth on the medial side (Fig. 8).

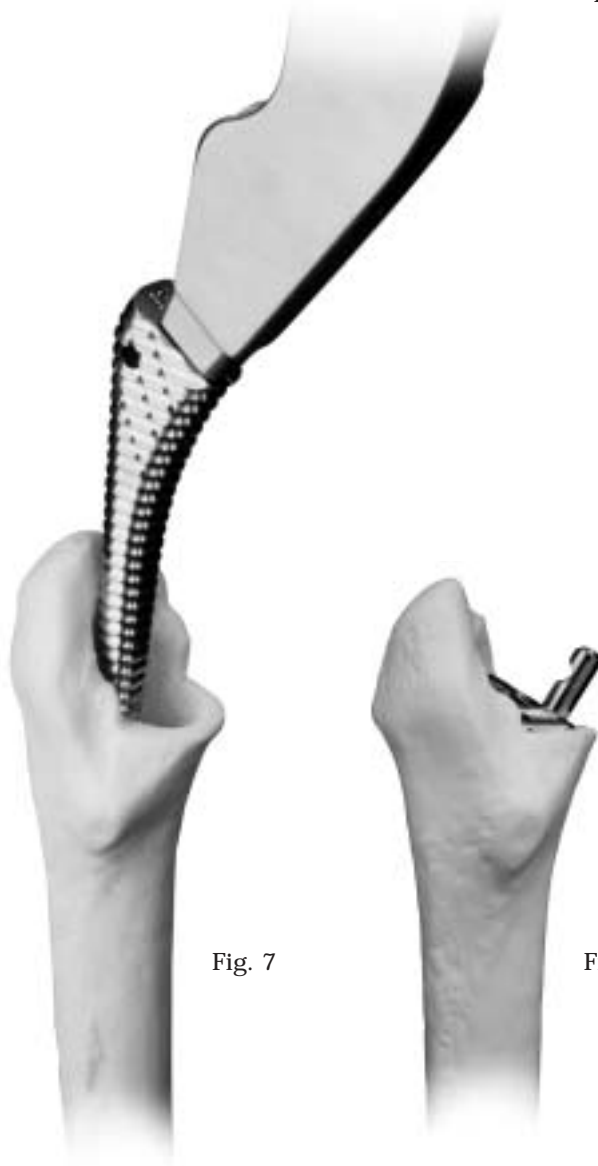

Fig. 7

Fig. 8

If medial cortical erosion is present, seat the rasp to the level of the new collar height. For example, if a 20mm block will be used, the rasp should have 20mm of proximal teeth showing above the level of the medial cortex (Fig. 9). If a 10mm block will be used, the rasp should have 10mm of proximal teeth showing above the level of the medial cortex.

Rasp the femoral canal with sequential incremental sizes until the cortical envelope is filled.

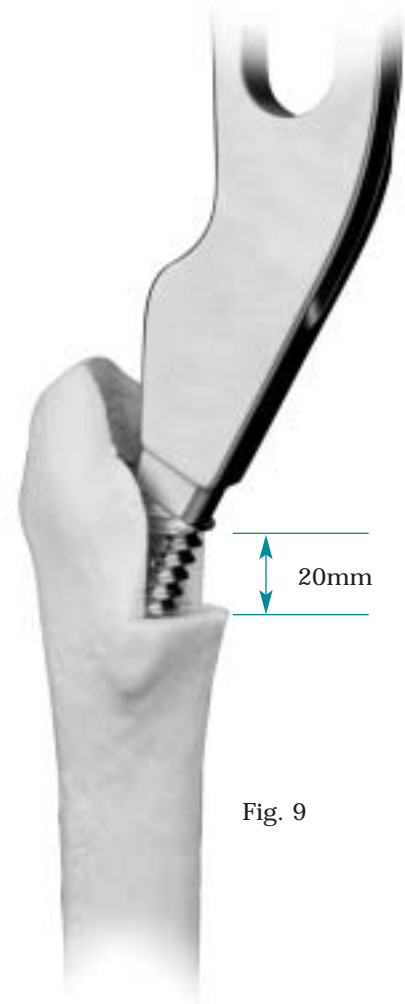


Fig. 9

Trial Reduction (optional)

If desired, and if the rasp is stable in the canal, a trial reduction can be performed (Figs. 10 & 10a). Lap pads or Ratex sponges can be used around the rasp to provide stability in the canal. The Cone Collar Provisionals are engraved with “CRC” for easy identification. There is a Cone Collar Provisional for each of the four implant sizes. Assemble the Cone Collar Provisional to the rasp trunnion. Then insert the desired femoral head provisional and perform the trial reduction.

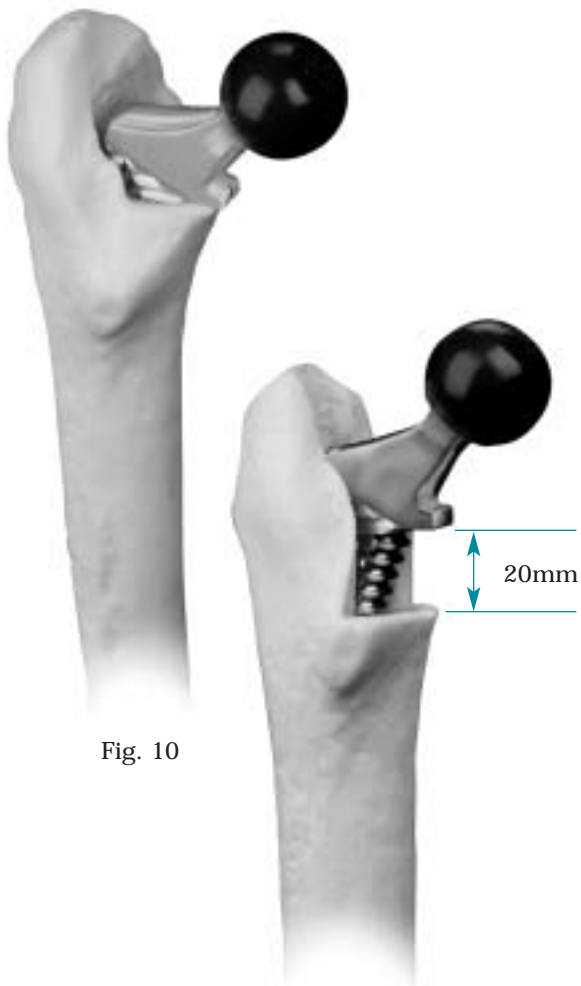


Fig. 10

Fig. 10a

Distal Reaming (optional)

In some cases, however, distal reaming may be helpful in preparing the canal to accept the selected implant. **Remember that all sizes of the VerSys CRC Implant extend beyond the rasp envelope.**

Use straight reamers (Figs 11 & 11a) when enlarging the diaphysis. The chart shows the distal dimensions for the four body sizes.

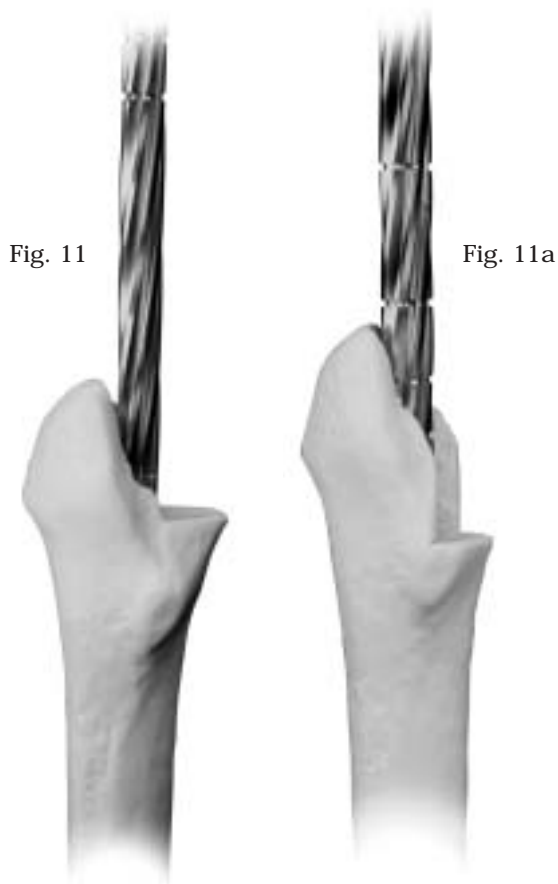
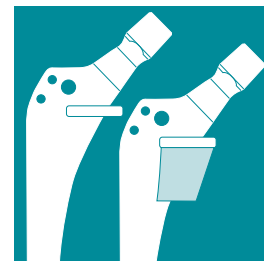


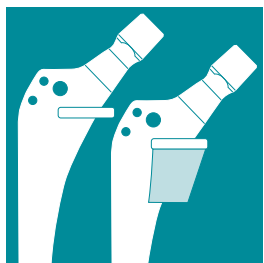
Fig. 11

Fig. 11a

Implant Size	Distal Dimension*	Reamer Dia. for 1.5mm Cement Mantle
Size 13	9mm	12mm
Size 15	11mm	14mm
Size 17	11mm	14mm
Size 19	13mm	16mm

* Dimension measured just above the tapered distal tip.





The amount of reaming will depend on the length of implant chosen and the amount of femoral bowing. In all cases, and especially those with excessive femoral bowing, insert the trial provisionals to make sure the implant passes freely. Care should be used when advancing the provisional in the canal to avoid perforation of the femoral cortex. If the provisional does not pass freely, it may be necessary to ream the distal canal with a flexible reamer by an additional 1-2mm to allow insertion of the stem, or a smaller implant should be used. In extreme cases, osteotomizing the femur to correct the deformity may be required. This should be determined during preoperative planning.

Inserting Provisional Stems

Select the provisional stem based upon rasp size or preoperative planning. If needed, attach the provisional calcar block that matches the osteotomy cut onto the provisional stem. The two pegs of the modular provisional block have C-rings that hold the block firmly to the collar (Fig. 12).

If using a Distal Centralizer, use the *VerSys* IM Canal Sizers to determine the size of the Provisional Distal Centralizer which will pass freely into the canal (Figs. 13 & 13a). If the canal sizer is tight in the canal, choose a provisional distal centralizer one size smaller than the size of the canal sizer.



Fig. 12

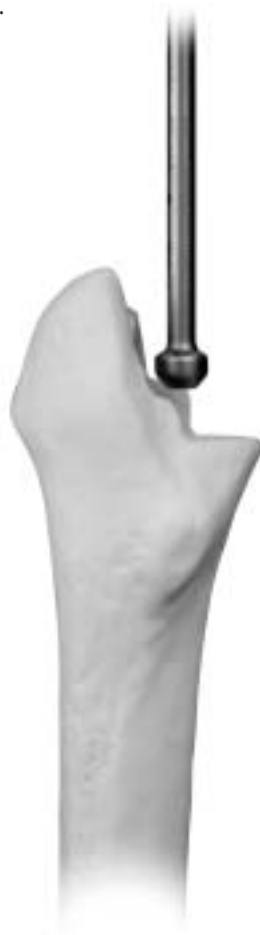

Fig. 13



Fig. 13a

Attach the Provisional Distal Centralizer to the provisional stem (Fig. 14). Turn the Provisional Distal Centralizer clockwise on the threads of the provisional stem until it will no longer turn. Then make a visual check to ensure it is completely on.

Provisional Distal Centralizers are available in 1mm increments. Be aware that although Distal Centralizers are less effective when used below the isthmus, they still prevent the tip from contacting endosteal cortex. In addition, the Provisional Distal Centralizers function to help stabilize the distal tip of the implant during the trial reduction of the hip.

Important: Insert the provisional stem assembly into the femoral canal (Fig. 15) to verify that the final implants will fit the femoral anatomy. Care should be used when advancing the provisional in the canal to avoid perforation of the femoral cortex.

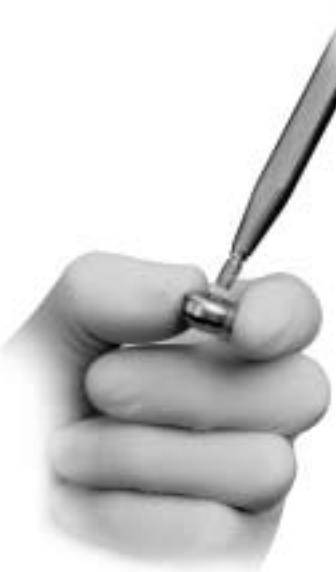

Fig. 14

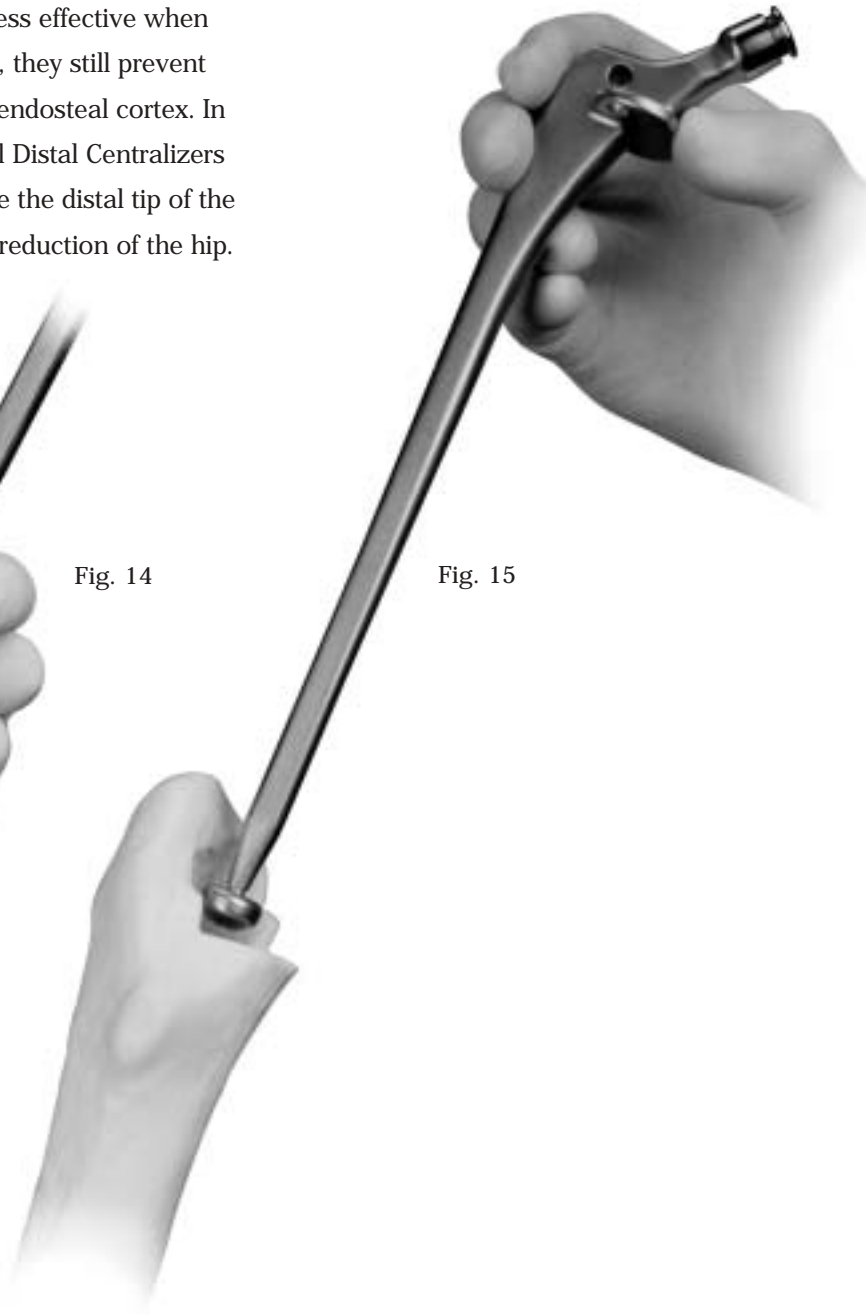
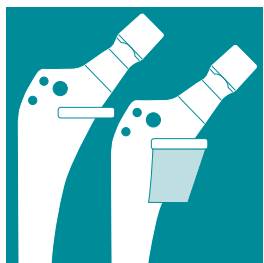


Fig. 15



Trial Reduction

Lap pads or Ratex sponges can be used around the provisional to provide stability in the canal. Mark the version on the medial neck with methylene blue. Adjust the provisional to match the rasp anteversion. Then press the provisional femoral head firmly onto the provisional stem's taper (Fig. 16). The provisional taper has a C-ring that holds the provisional femoral head onto the provisional stem.

Reduce the hip and choose the appropriate neck length. Carefully evaluate stability and leg length, and ensure that there is no impingement. If the soft tissue tension is inadequate, choose a longer neck length, or a larger modular block. A large modular block is preferable to avoid using a head with a skirt. Remove the provisional components from the femoral canal.

Canal Preparation

Place a distal cement restrictor or cement plug at a depth to allow for 1-2cm of cement beyond the tip of the prosthesis. If the tip is

below the isthmus, you may want to use a small amount of cement to secure the plastic restrictor in place. Next, cover or occlude any perforations or windows in the femoral canal. Then, prepare the canal with pulsatile lavage irrigation and dry it thoroughly.

Assembling the Implant

Prepare the implant for implantation. If the use of a calcar block is required, attach the appropriate block as determined with the provisional stem. Insert the first screw, but do not tighten it completely (Fig. 17). Insert the second screw and alternate between turning the two screws until both screws are secure and the block is seated flat against the collar. Do not over-tighten screws (Fig. 18).

If a distal centralizer is to be used, select a distal centralizer that matches the size of the distal provisional centralizer used with the provisional implant.

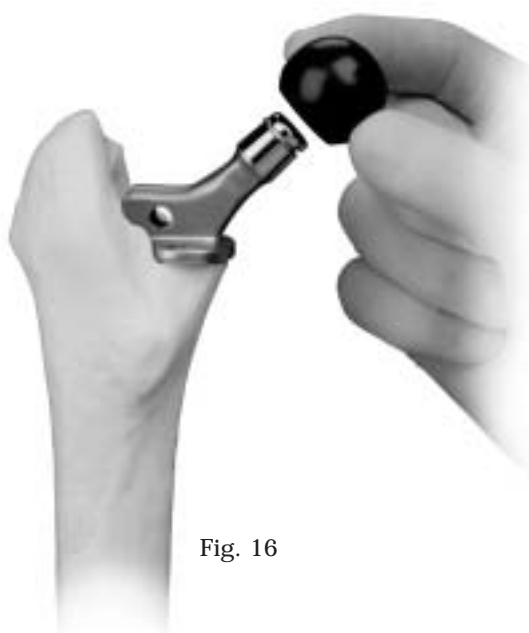


Fig. 16



Fig. 17

Fig. 18

The distal centralizer's inner diameter has a taper through its length similar to a head/neck taper. Before attaching the distal centralizer to the stem, apply a thin layer of cement to the distal tip or fill the tapered hole in the centralizer with cement. This will help achieve a solid bond between the stem and distal centralizer. To attach the centralizer, insert the stem tip through the opening on the flat side of the centralizer so the tapered ends of the centralizer flanges will be most distal on the stem (Fig. 19).

If desired, attach the femoral head that matches the provisional head, or use the provisional head and neck to confirm sizing.

Cement Introduction and Stem Insertion

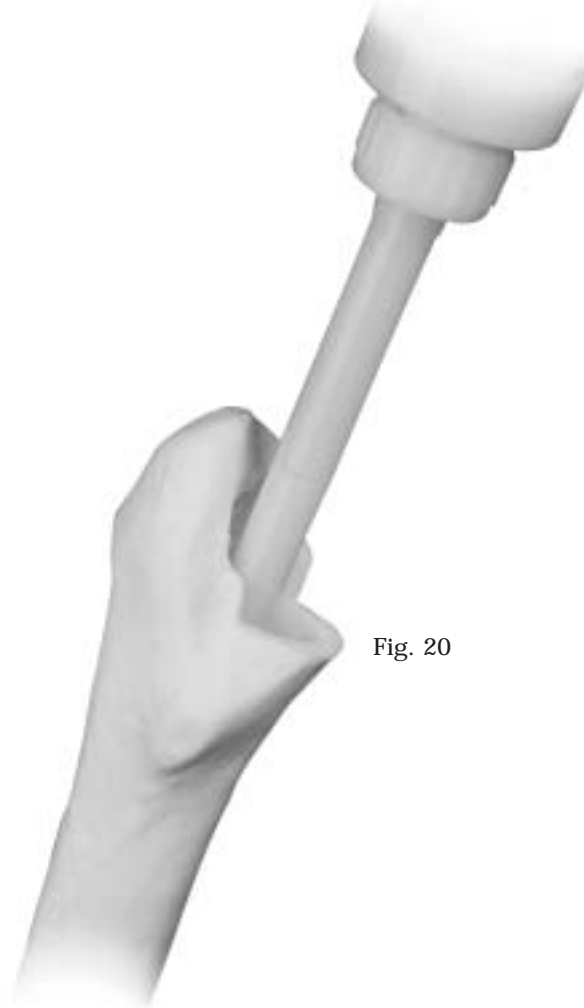
Mix the cement in a vacuum or use a centrifuge to reduce porosity. Introduce the cement into the femoral canal in a retrograde manner (Fig. 20), then firmly pressurize. For long stems, use a long cement nozzle or attach a 28 French chest tube to the standard nozzle. Then insert the pre-assembled prosthesis. Insert the stem with the same version as the trial. Moderate resistance confirms good pressurization. Be sure to achieve maximum calcar contact for effective load transfer to the femur. Allow the cement to harden, then remove all residual cement.



Fig. 19



Fig. 20





If the final femoral head was not attached before inserting the stem, attach a trial femoral head and perform a trial reduction to confirm the proper neck length selection. Assess the leg length, range of motion, stability, and abductor tension one final time.

Being sure that the neck taper is clean and dry, place the femoral head onto the taper. Use a twisting motion to help ensure that

the head is securely locked onto the neck taper. If desired, cover the head with a lap pad. Strike the femoral head once with the Femoral Head Impactor and mallet (Figs. 21 & 21a). Then test the security of the head by trying to remove it by hand.

After obtaining hemostasis, insert a *Hemovac*[®] Wound Drainage device, if necessary. Close the wound in layers.



Fig. 21

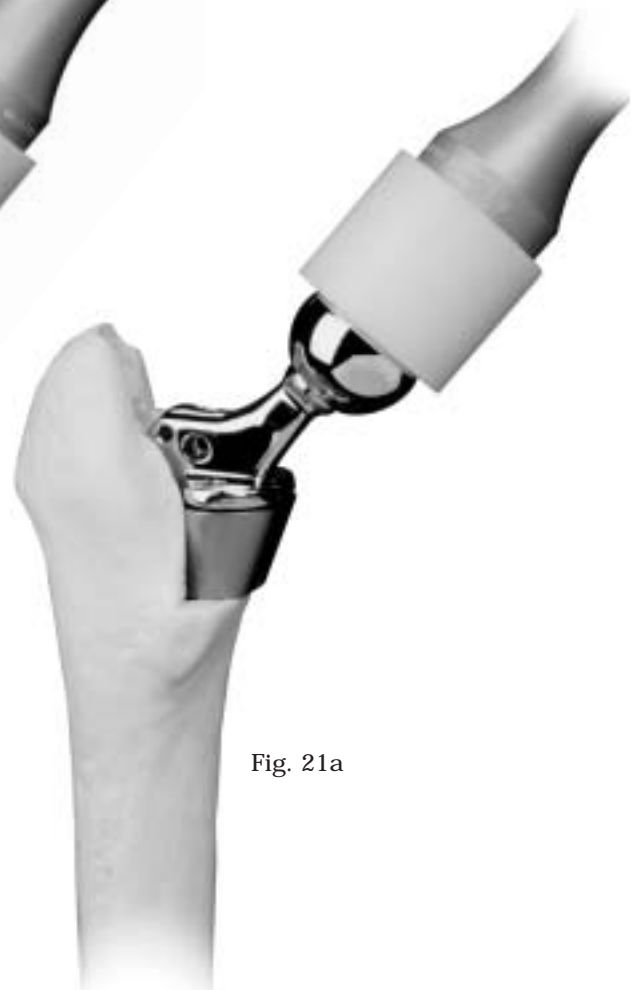

Fig. 21a



Please refer to the package inserts for complete product information, including contraindications, warnings, precautions, and adverse effects.